



Steroid Injection Popliteal Cyst | Treatment of Popliteal (Baker) Cysts With Ultrasound ...

In 30 osteoarthritic knees with symptomatic popliteal cysts, a single intra-articular triamcinolone acetonide injection achieved significant improvement in pain, swelling, range of motion, cyst size, and wall thickness at follow-up imaging after 4 weeks. 1 Aspiration of 26 popliteal cysts under ultrasound guidance with steroid injection. Eight of the 9 nonoperative treatment studies utilized corticosteroid injections. The most recent studies have advocated for ultrasound-guided intracystic injection with possible cyst fenestration. Most operative studies utilized an arthroscopic approach to enlarge the communication with the joint space.

? VISIT OUR STORE: <https://t.co/gowjMiqf6A>

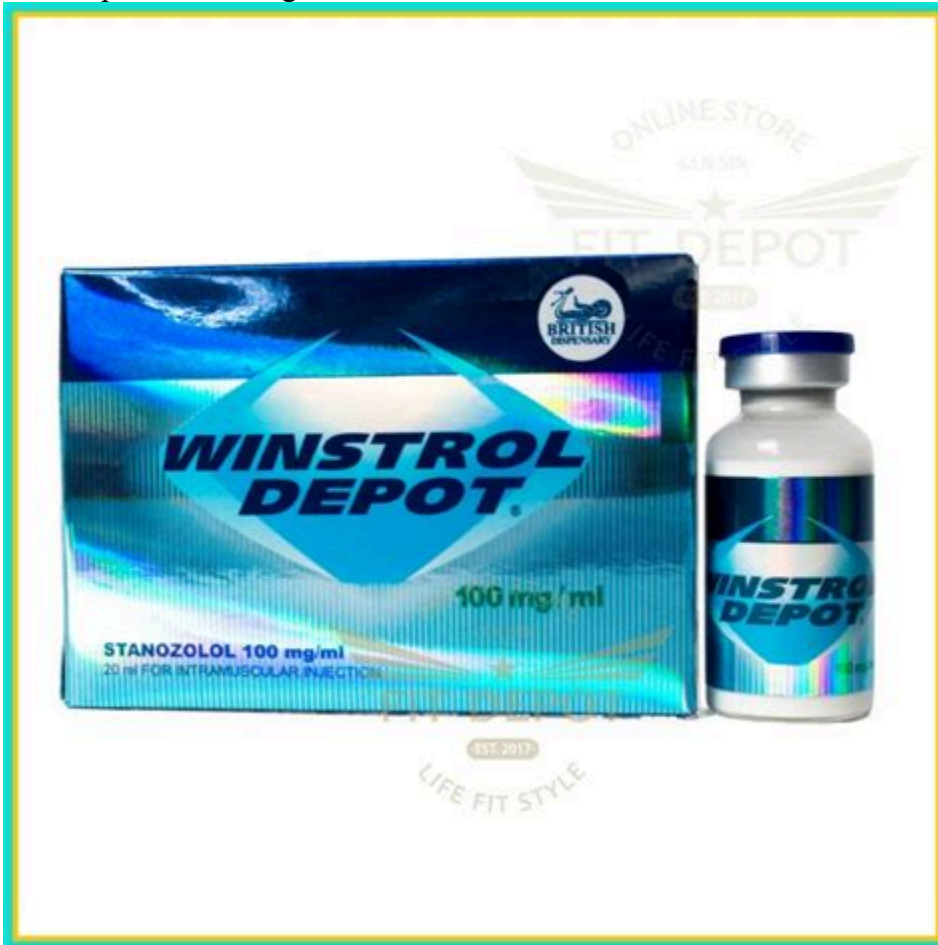Popliteal Cysts: A Systematic Review of Nonoperative and ...

- in protracted cases, cysts may respond to aspiration and steroid injection, (note that unlike adults, the cyst may not be intra-articular, and therefore, may respond to aspiration); - references - Popliteal cysts in children. The case against surgery. A Baker's cyst, also known as a popliteal cyst, is a pocket of joint fluid that forms a lump behind the knee. Often a Baker's cyst is painless, but occasionally this pocket of fluid can tear open and drain into the tissues of the lower leg, causing pain and swelling. Symptoms include: Swelling behind the knee that may increase when a person stands.



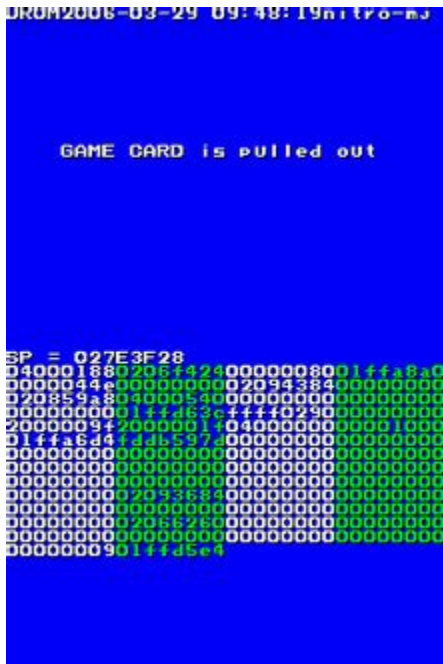Ultrasound-guided aspiration and steroid injection of a ...

Ultrasound-guided aspiration and steroid injection of a posterior cruciate ligament ganglion cyst: report of a case. effusion and occasional swelling with a palpable mass in the popliteal region of the knee. Percutaneous aspiration followed by a corticosteroid injection of a ganglion cyst has either a diagnostic or therapeutic meaning and.



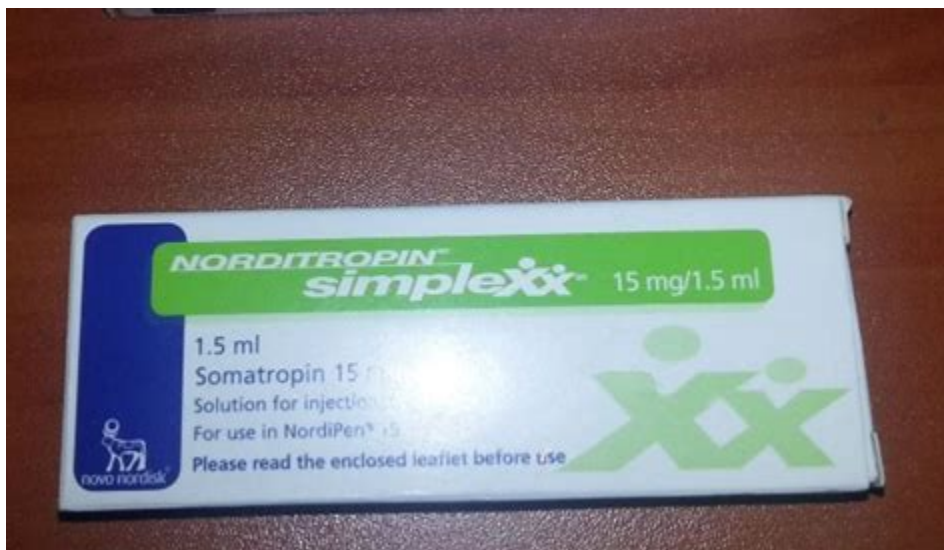
Ultrasound-guided aspiration and steroid injection of the cyst were planned. Open in a separate window Figure 1. Coronal (A) and axial (B) proton density fat-suppressed magnetic resonance images of a knee show a small cystic structure (straight arrows) within the anterior margin of the popliteus tendon (asterisks), reflecting a ganglion cyst. [look these up](#)

Symptomatic Ganglion Cyst of the Popliteus Tendon Treated ...




The treatment of Baker's Cysts are based on its presentation, asymptomatic cysts are currently managed conservatively, symptomatic cysts are treated with joint aspiration and Corticosteroid injection, which have shown according to literature a decrease of the cyst size in approximately two-thirds of patients within 2-7 days but only complete disappearance in approximately 7 %.

Symptomatic Ganglion Cyst of the Popliteus Tendon Treated ...



Steroid injection. Your doctor may inject a corticosteroid medication into your knee joint to reduce inflammation. Aspiration. In this procedure, your doctor numbs the area around the cyst, then uses a needle to drain the excess fluid from the joint. Aspiration is often performed using ultrasound to guide the placement of the needle.



Ultrasound guided popliteal cyst (Baker's cyst) aspiration and steroid injection, by Prof Murat Karkucak MD [my review here](#)

Baker's Cyst (Popliteal Cyst) - OrthoInfo - AAOS

- Baker's Cyst / Popliteal Cysts : Wheelless' Textbook of ...
- Ultrasound guided popliteal cyst (Baker's cyst) aspiration ...
- PRP vs Corticosteroid in Baker's Cyst - Full Text View ...