

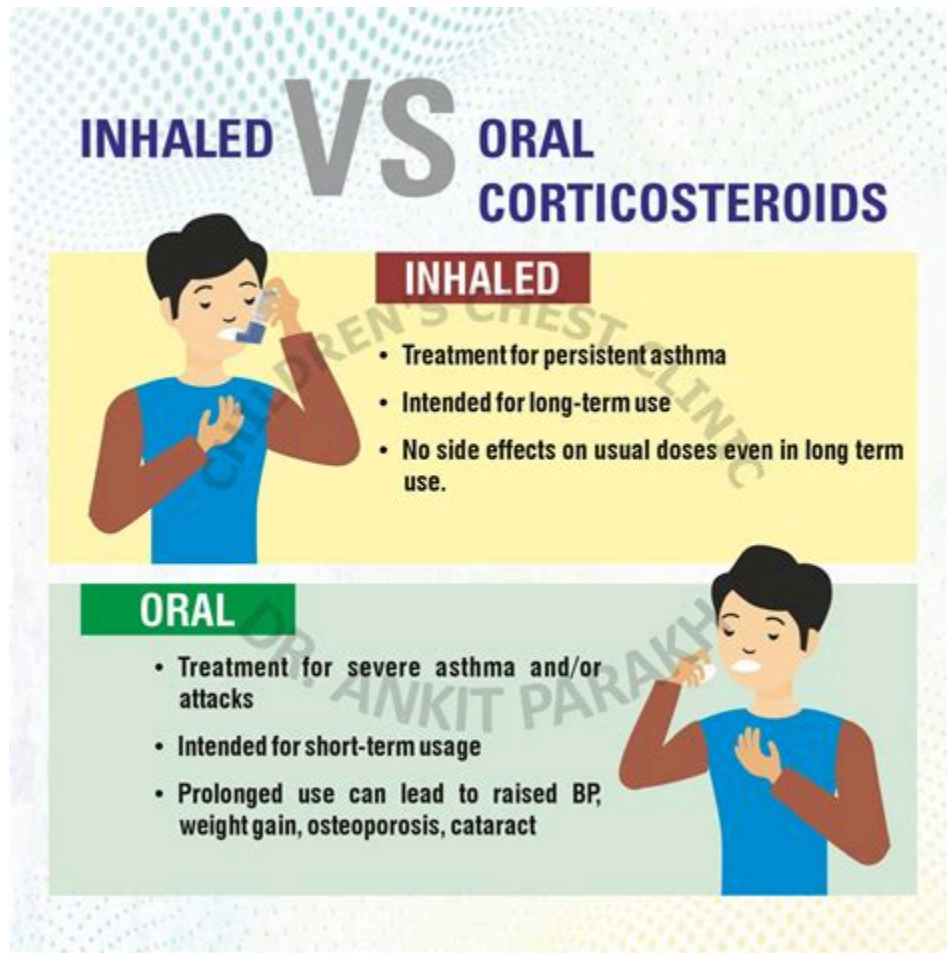
An ulcer is a break in the oral epithelium. . RAU is characterised by recurrent episodes of single or multiple mouth ulcers with no identifiable cause, and therefore diagnosis can only be made following exclusion of local or medical causes. . Topical corticosteroids suppress the local flora and can cause an overgrowth of *Candida* spp, which .



????? SHOP OUR ONLINE STORE ??????

## Oral Lesions and Corticosteroids | Pocket Dentistry

# INHALED VS ORAL CORTICOSTEROIDS



The infographic is divided into two horizontal panels. The top panel has a yellow background and is titled 'INHALED'. It features an illustration of a man in a blue shirt using an inhaler. The bottom panel has a light green background and is titled 'ORAL'. It features an illustration of the same man in a blue shirt holding a white pill to his mouth. A large, faint watermark 'ANKIT PRAKASH' is visible across the center of the infographic.

### INHALED

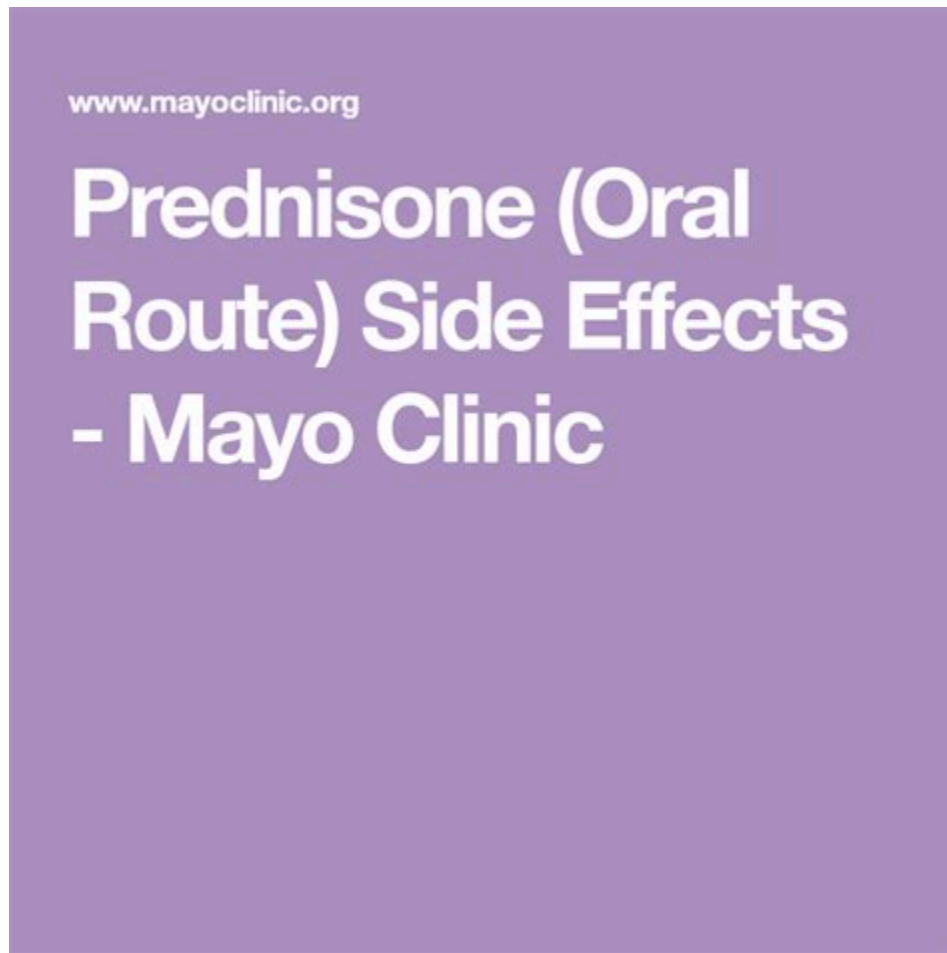
- Treatment for persistent asthma
- Intended for long-term use
- No side effects on usual doses even in long term use.

### ORAL

- Treatment for severe asthma and/or attacks
- Intended for short-term usage
- Prolonged use can lead to raised BP, weight gain, osteoporosis, cataract

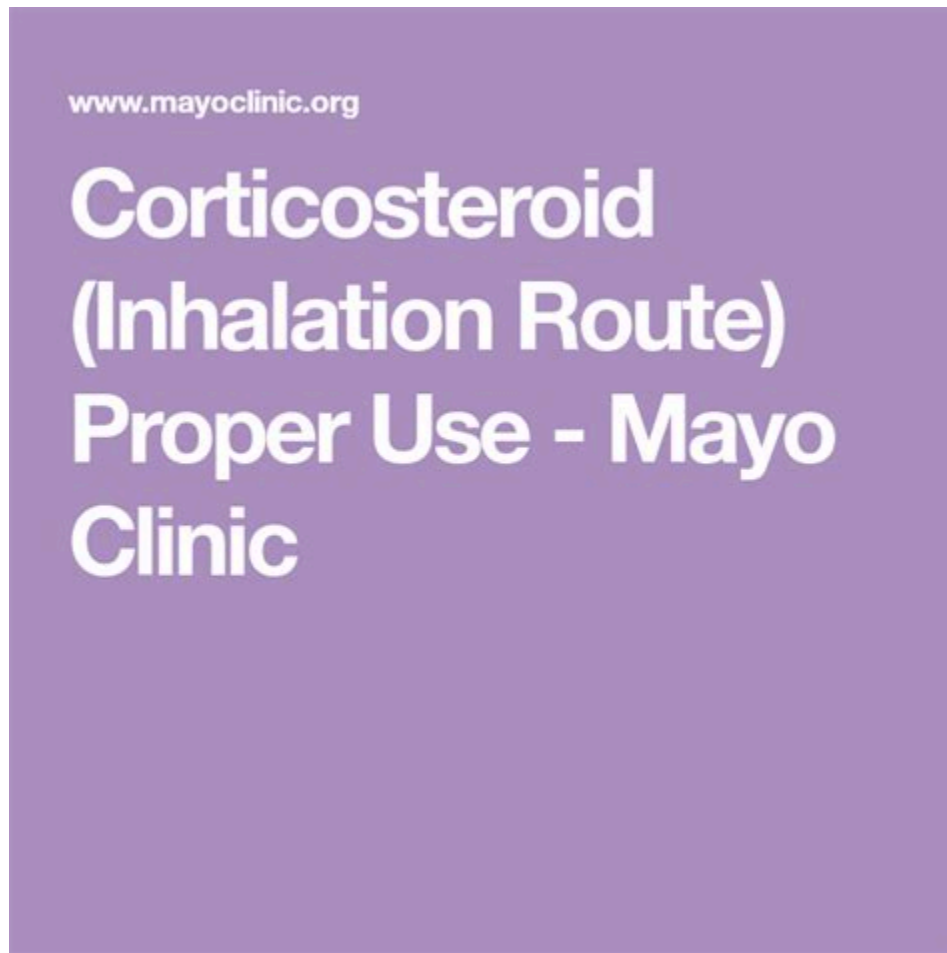Hydrocortisone buccal tablets - Brand name: Corlan Find out how hydrocortisone buccal tablets treat mouth ulcers and how to use them. About hydrocortisone buccal tablets Who can and cannot use them How and when to use them Side effects

## **Prednisone (Oral Route) Side Effects - Mayo Clinic**



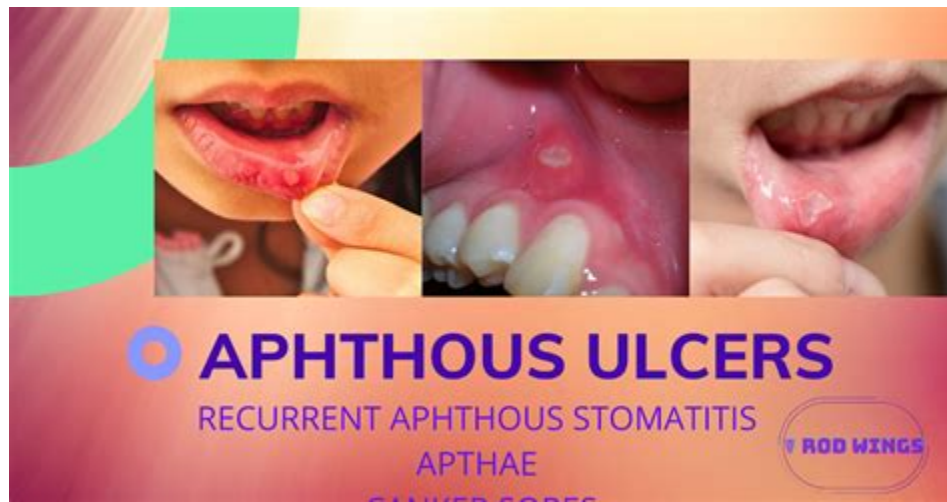
numbness or tingling in the arms or legs. pounding in the ears. shortness of breath. swelling of the fingers, hands, feet, or lower legs. trouble thinking, speaking, or walking. troubled breathing at rest. weight gain.

## Corticosteroid (Dental Route) Proper Use - Mayo Clinic



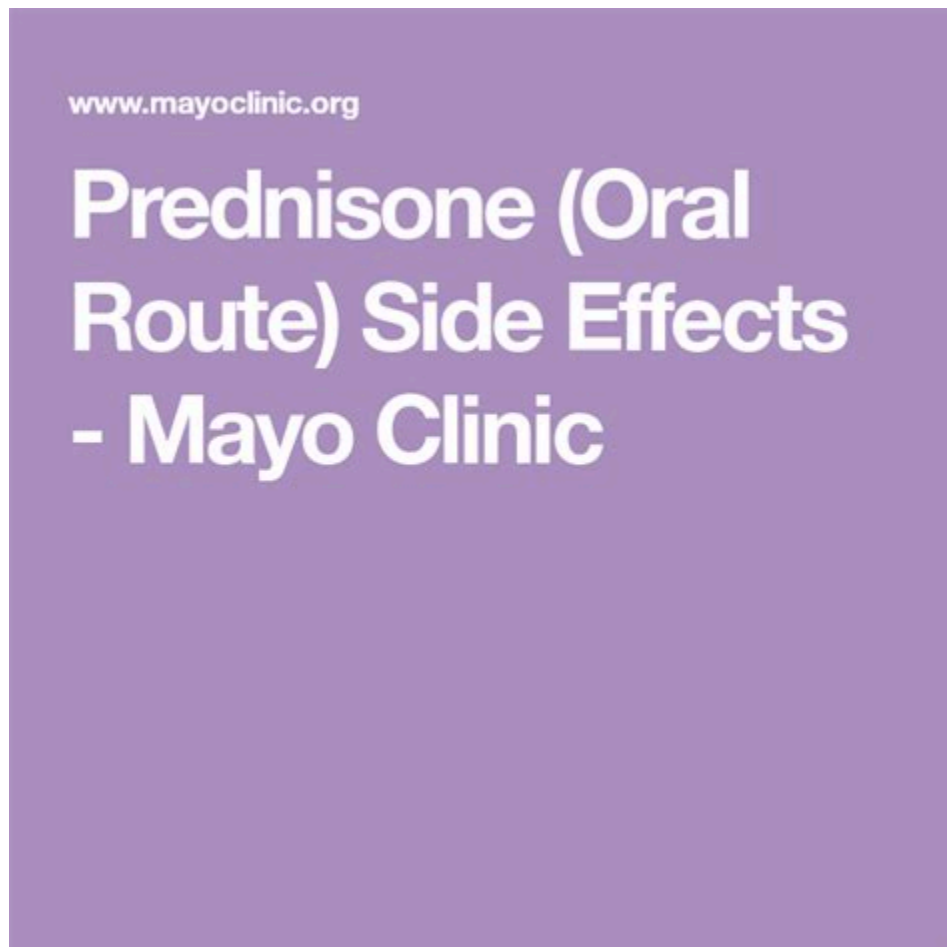
Oral thrush — also called oral candidiasis (kan-dih-DIE-uh-sis) — is a condition in which the fungus *Candida albicans* accumulates on the lining of your mouth. *Candida* is a normal organism in your mouth, but sometimes it can overgrow and cause symptoms. Oral thrush causes creamy white lesions, usually on your tongue or inner cheeks.

## Management of Aphthous Ulcers | AAFP



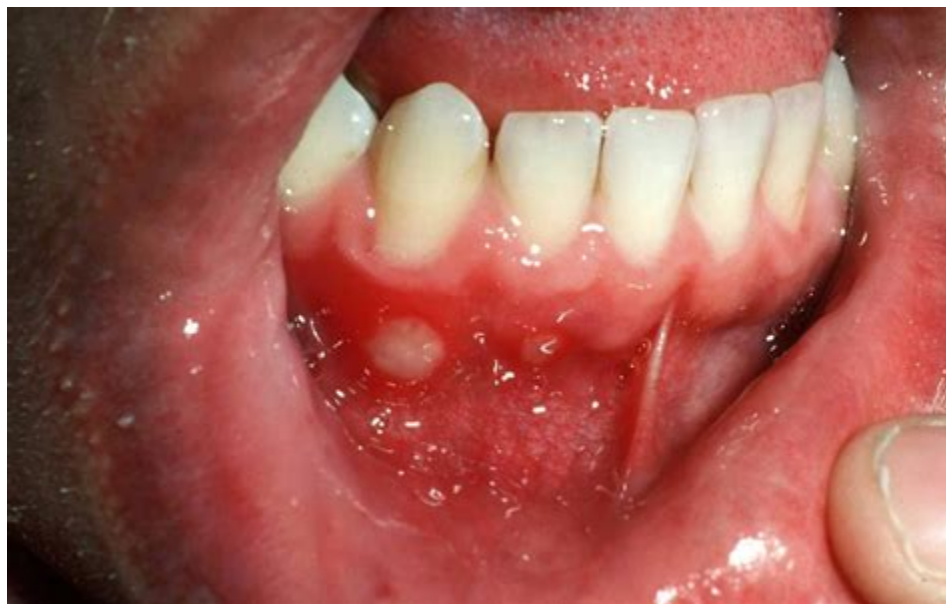Although many mouth ulcers heal on their own without treatment, hydrocortisone muco-adhesive tablets can help mouth ulcers heal more quickly. They also help to ease the pain. Muco-adhesive buccal tablets are designed to be placed next to the ulcer, and to dissolve slowly in your mouth.

## Methylprednisolone (Oral Route) Side Effects - Mayo Clinic



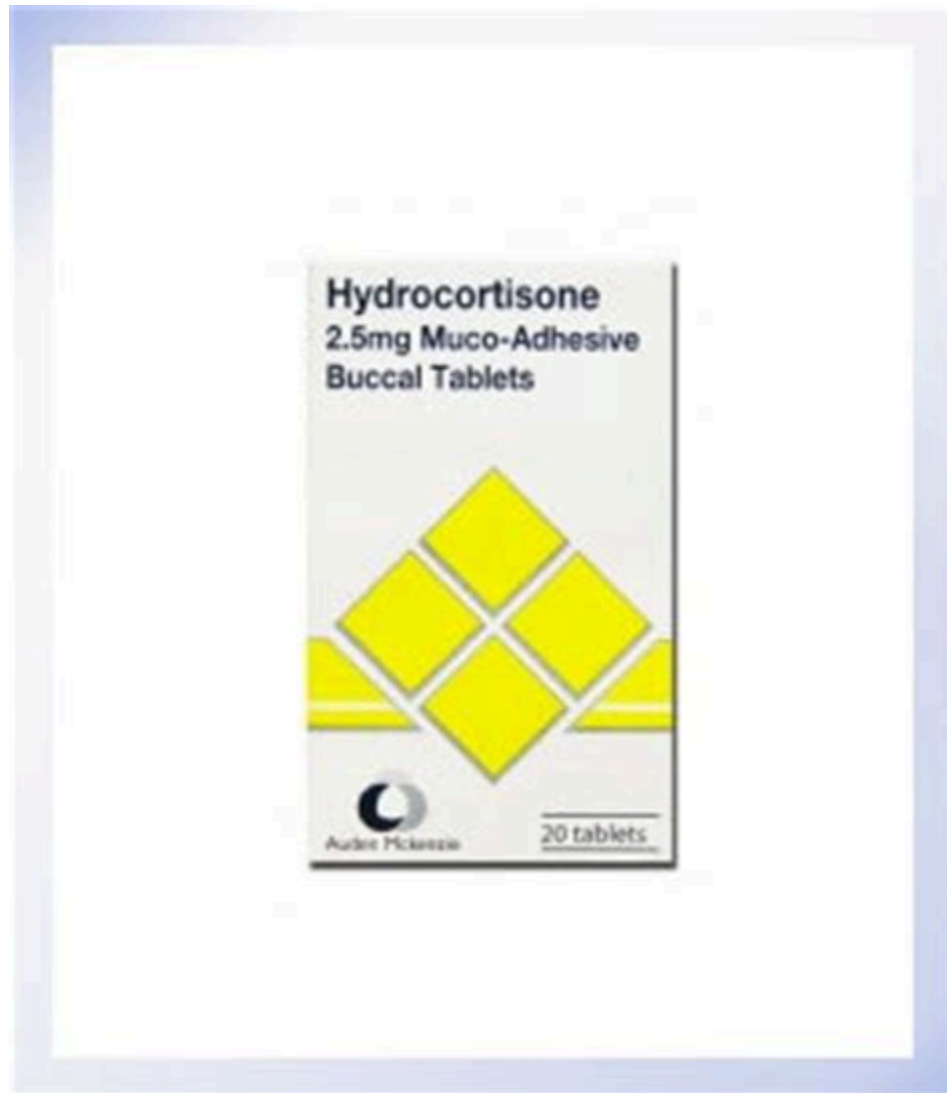
Prednisone is a steroid medication that can treat various conditions, such as arthritis, asthma, lupus and cancer. However, it can also cause side effects, such as weight gain, mood changes, high blood pressure and osteoporosis. Learn more about the possible risks and benefits of prednisone from Mayo Clinic, a trusted source of health information.

### **Aphthous ulcer | Health topics A to Z | CKS | NICE**



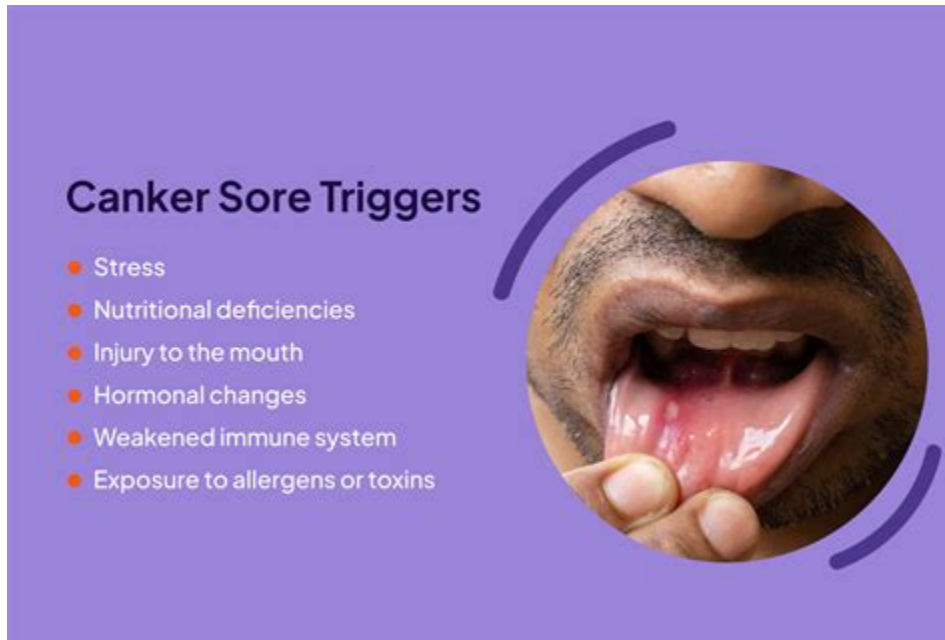
Benzydamine hydrochloride mouthwash and spray are licensed for the relief of painful inflammatory conditions associated with a variety of ulcerative conditions, as well as for discomfort of tonsillectomy and post-irradiation mucositis.

## Hydrocortisone muco-adhesive tablets for mouth ulcers



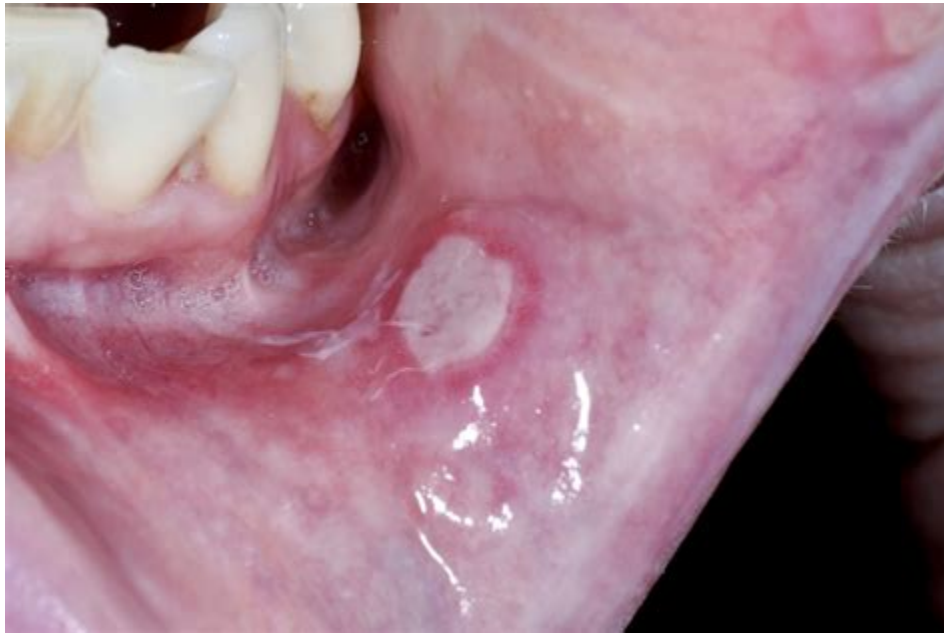In Germany, the only drugs that have been approved to treat oral aphthous ulcers are corticosteroids, topical antiseptic/anti-inflammatory agents such as triclosan and diclofenac, and local anesthetics such as lidocaine. Antiseptic agents and local anesthetics should be tried first; if these are ineffective, topical corticosteroids should be used.

## Canker sore - Diagnosis and treatment - Mayo Clinic



The application of topical steroids such as 0. 05% clobetasol propionate gel, 0. 1-0. 05% betamethasone valerate gel, 0. 05% fluocinonide gel, 0. 05% clobetasol ointment or cream, and 0. 1% triamcinolone acetonide ointment is recommended for the treatment of oral lesions. Oral steroid drugs are recommended in severe cases.

## Mouth Ulcers: Types, Causes & Treatment - Cleveland Clinic



Recurrent aphthous stomatitis (canker sores, or aphthous ulcers) is the presence of small, painful sores (ulcers) inside the mouth that typically begin in childhood and recur frequently. Mouth injury, stress, and some foods may trigger an attack. People feel burning pain, and a day or so later a canker sore develops



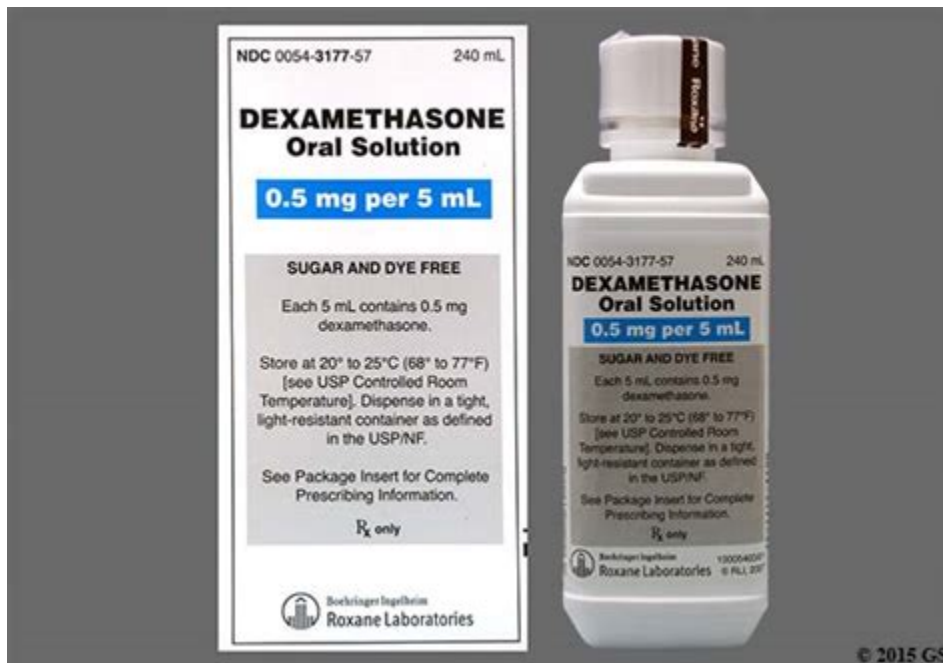on the soft tissue of the mouth.

## How Lupus Affects Your Oral Health - MSN



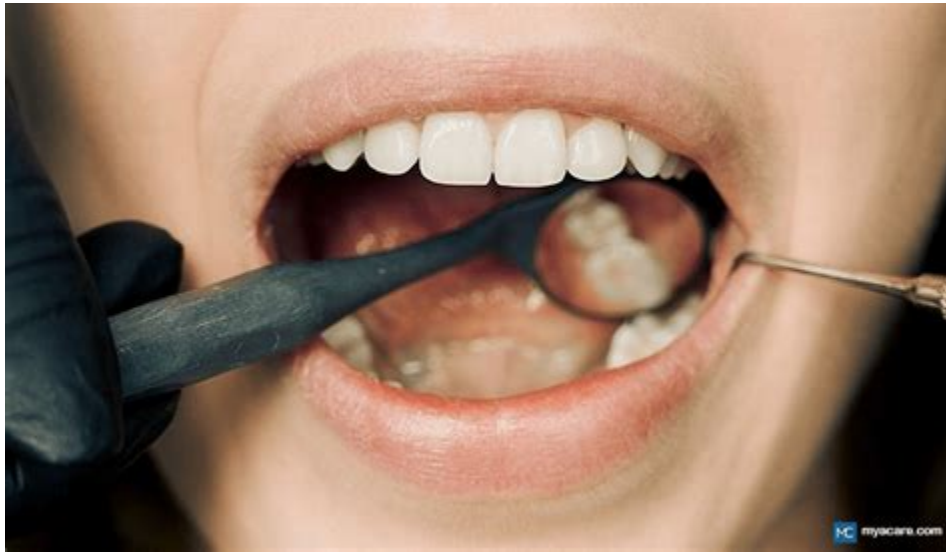If you have mouth sores, it may help to use a soft-bristled brush to avoid further irritation. Treatment for oral sores or ulcers may involve topical or systemic medications, such as steroids or .

## Dexamethasone Oral Solution: Uses & Side Effects - Cleveland Clinic



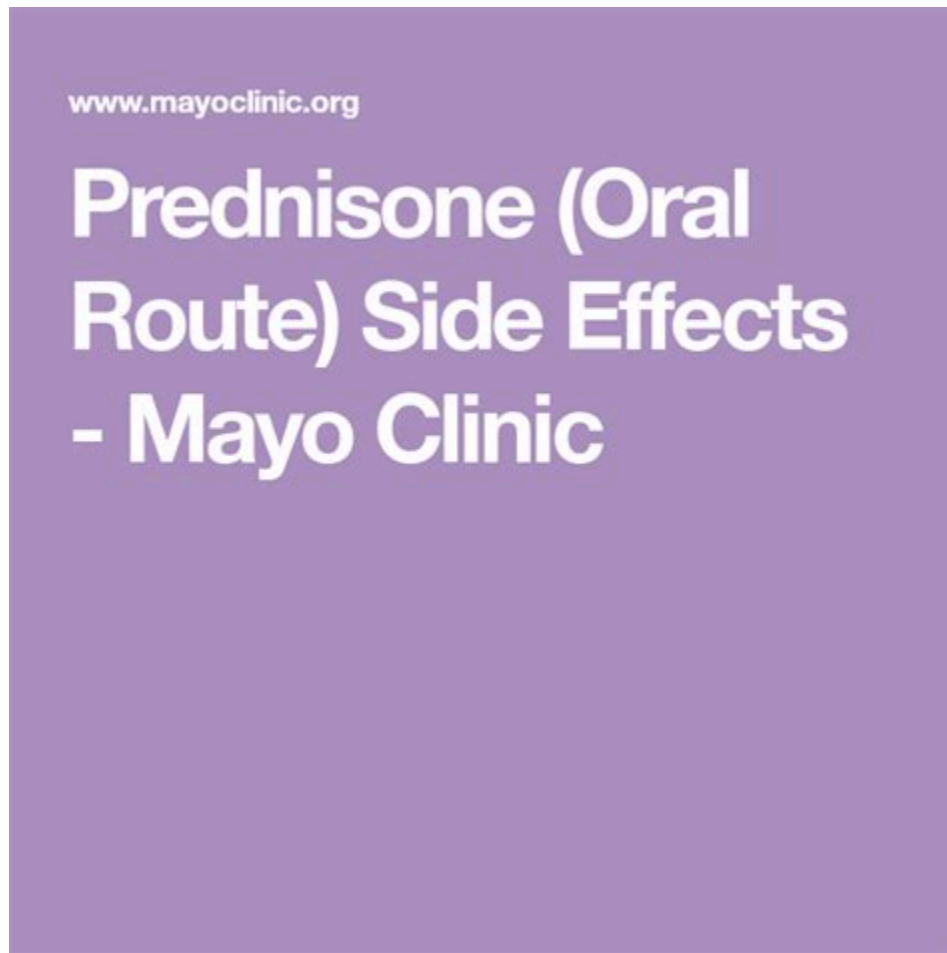
Proper Use. Drug information provided by: Merative, Micromedex ®. To use hydrocortisone or triamcinolone dental paste: Using a cotton swab, press (do not rub) a small amount of paste onto the area to be treated until the paste sticks and a smooth, slippery film forms. Do not try to spread the medicine because it will become crumbly and gritty.

## The Effects of Steroids on Oral Health: Applications and Side Effects



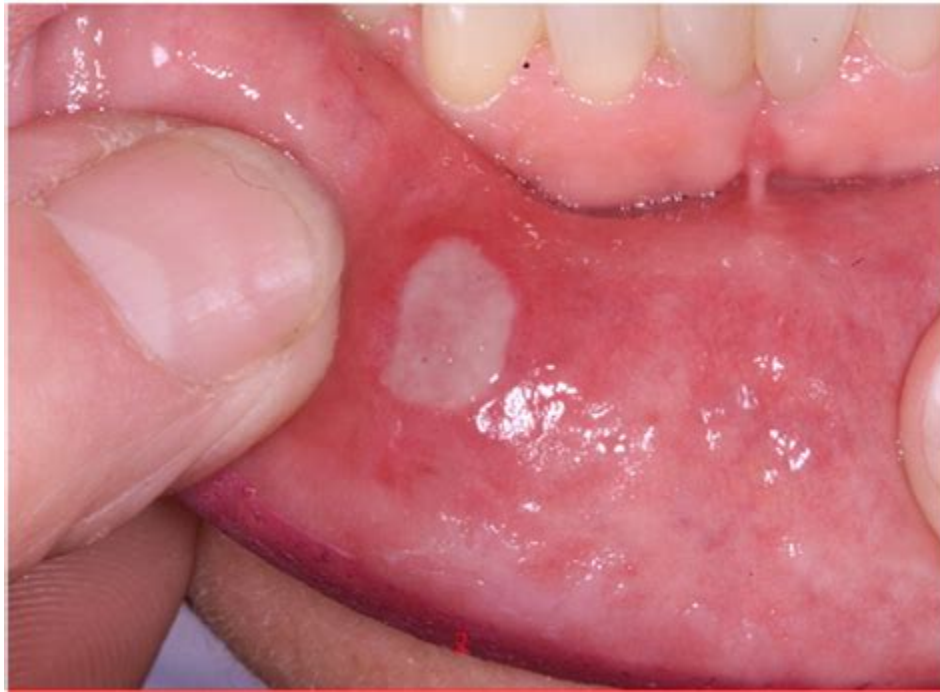Oral steroid medications when severe canker sores don't respond to other treatments. But because of serious side effects, they're usually a last resort. Cautery of sores During cautery, an instrument or chemical substance is used to burn, sear or destroy tissue. Debacterol is a topical solution designed to treat canker sores and gum problems.

## **Prednisone (Oral Route) Side Effects - Mayo Clinic**



Oral trauma. Anxiety or stress. Certain foods (including chocolate, coffee, peanuts, and gluten-containing products). Vitamin and mineral deficiencies. Stopping smoking. Hormonal changes related to the menstrual cycle. Investigations are generally unnecessary.

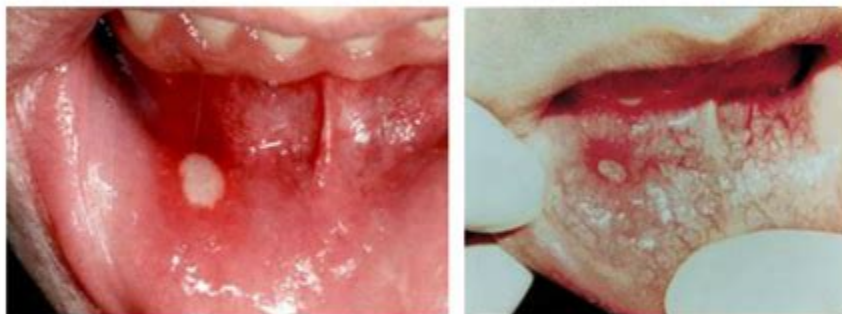## Recurrent Aphthous Stomatitis - Mouth and Dental Disorders - Merck .



1. Rinse oral cavity with salt water (1 tsp salt in one cup of water). 2. Wash hands prior to applying ointment. 3. Apply ointment to oral lesions 3-4 times daily using a cotton tip applicator. Lesions Confined to the Gingival Tissue The clinician can fabricate custom-fitted trays to be filled with the compound described above.

### The Treatment of Chronic Recurrent Oral Aphthous Ulcers

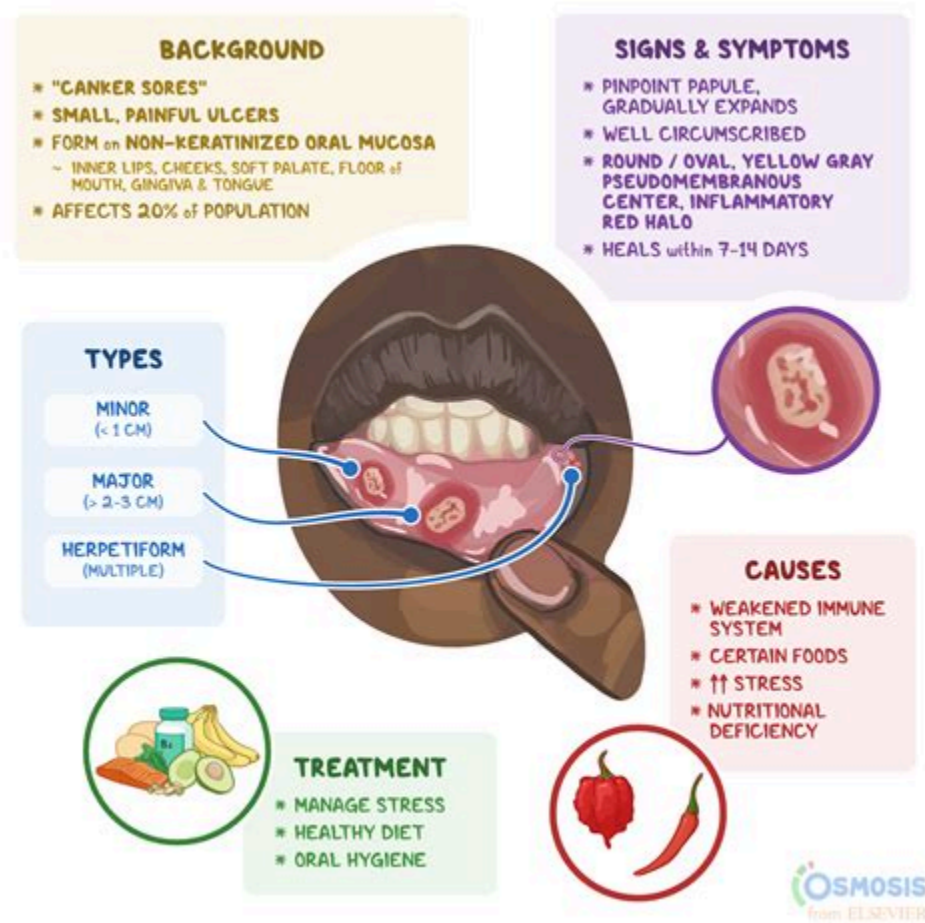
#### Aphthous Ulcers Clinical Presentation



- Painful open sores inside the mouth caused by a break in the mucuous membrane
- Typically white color / erythematous around lesion.

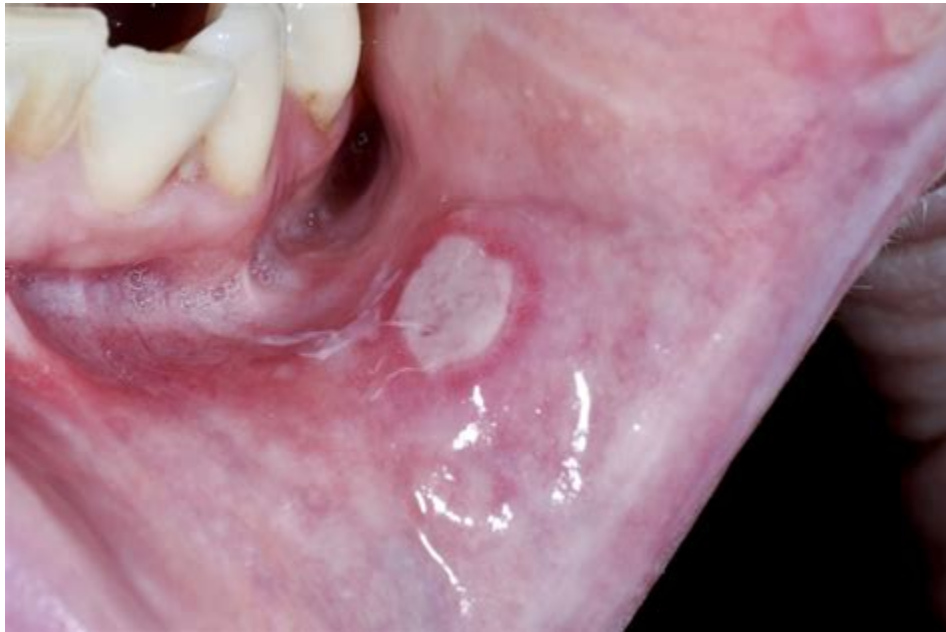
Aphthous ulcers are a common and painful problem. Benign aphthae tend to be small (less than 1 cm in diameter) and shallow. Aphthous ulcers that occur in conjunction with symptoms of uveitis .

## Management of Common Oral Sores - U. S. Pharmacist



This medication is used for the temporary relief of symptoms from mouth sores due to injury. This drug comes in a dental paste that allows it to stick to the inside of the mouth /cheeks/gums. .

## Oral ulceration and inflammation | Treatment summaries | BNF | NICE



Oral ulceration: causes and management Patients often present in community pharmacy with mouth ulcers. This article describes the aetiology, presentation and treatment options for six lesion types. Oral health 19 March 2019 Science Photo Library The majority of mouth ulcers are painful and can adversely affect eating and drinking.

## Treatment of complex oral lesions - The Pharmaceutical Journal

Topical therapies used in oral medicine			
Preparation	Therapy	Recommended dose	Precautions
Chlorhexidine 0.2% mouthwash	Topical antiseptic	10ml rinsed in mouth for one minute twice a day	None relevant
Benzydamine 0.15% mouthwash	Topical anti-inflammatory	10-15ml rinsed in mouth every 1.5-3 hours when required. Not usually longer than seven days' duration	Only used for patients aged 13 years or older
Benzydamine 0.15% oro-mucosal spray	Topical anti-inflammatory	Four to eight sprays applied to affected area every 1.5-3 hours	None relevant
Orabase	Mucoadhesive	Used as required	None relevant
Betamethasone soluble tablets (used as a mouthwash)	Topical corticosteroid	500µg tablet dissolved in 20ml of water. Rinsed in mouth four times a day	Increased risk of candidal opportunistic infection
Hydrocortisone mucoadhesive buccal tablets	Topical corticosteroid	2.5mg tablet dissolved slowly in the mouth four times a day	Increased risk of candidal opportunistic infection
Clobetasol 0.05% ointment	Topical corticosteroid	Thin layer applied once or twice a day	Increased risk of candidal opportunistic infection
Fluocinolone 0.025% gel	Topical corticosteroid	Applied thinly once or twice a day	Increased risk of candidal opportunistic infection
Beclometasone 250µg inhaler	Topical corticosteroid	Two sprays applied to lesions up to four times a day	Increased risk of candidal opportunistic infection

Overview Mouth ulcers are often white or yellow in the middle with red around the edges. What is a mouth ulcer? A mouth ulcer is a sore that appears anywhere inside your mouth. These sores are usually red, yellow or white, and you might have one or several. You can get mouth ulcers on your: Gums. Tongue. Roof of mouth (palate). Inner cheeks.

## Oral ulceration: causes and management - The Pharmaceutical Journal

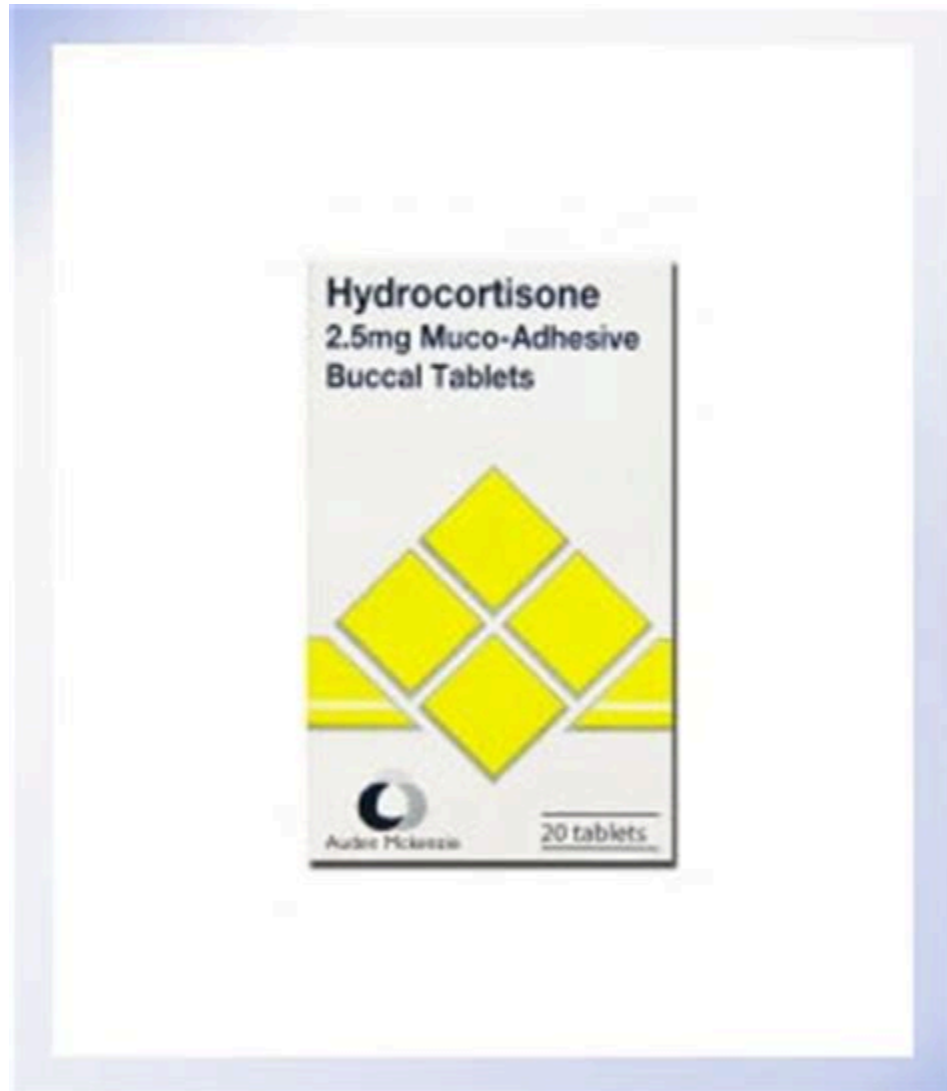
	Causative agent	Associated features	Initial investigations
Infection			
Recurrent ulcers	Hand foot and mouth disease: Coxsackie A virus or enterovirus 71, Herpes Simplex 1 and 2, HIV	Tingling prodrome, systemic features such as fever, lethargy, weight loss and recurrent illnesses.	Full blood count, swab for viral diagnostics, serology for HIV and virology. TB testing where appropriate.
Persistent ulcers	HHV 6, Varicella /Herpes Zoster, CMV, EBV, Syphilis, Tuberculosis		
Autoimmune disorders	Crohn's disease, Behcet's disease, Systemic Lupus Erythematosus, Coeliac disease, PFAPA syndrome, MAGIC syndrome	Systemic features such as weight loss, bleeding, lethargy, cycles of fever, diarrhoea, myalgia, arthralgia	Full blood count, inflammatory markers, ESR, autoantibodies, IgA, tissue transglutaminase.
Immune disorders	Immunodeficiency syndromes	Recurrent infections, failure to thrive	Full blood count, immunoglobulins, lymphocyte subsets, serology for HIV.
Trauma	Teething, dental appliances	History of trauma	
Vitamin deficiencies	Iron, B12, folate, vitamin C, magnesium, zinc	Poor diet, weight loss, skin and hair changes, pallor, tongue depapillation	Full blood count, haematinics, zinc, magnesium, Vitamin C levels
Neoplastic/haematological	Anaemia, leukaemia, agranulocytosis, cyclical neutropenia	Lethargy, fevers, pallor, tongue depapillation	Full blood count, LDH, urate, blood film
Idiopathic recurrent aphthous stomatitis	Normal haematology	Recurrent and healing completely between episodes	Full blood count, blood film, haematinics, viral swab for diagnostics

MAGIC syndrome, mouth and genital ulcers with inflamed cartilage; PFAPA syndrome, periodic fever, aphthous ulcers, pharyngitis and adenitis; TB, tuberculosis; ESR, erythrocyte sedimentation rate; HHV, human herpes virus; CMV, cytomegalovirus; EBV, Epstein-Barr virus; LDH, lactate dehydrogenase

The one commonly used is fludrocortisone. What are oral steroids used for? Oral steroids are used to

treat a large number of conditions, usually by reducing inflammation or the effect of the person's immune system. Some examples include: Inflammatory bowel diseases (for example, Crohn's disease, ulcerative colitis).

### **Hydrocortisone buccal tablets: steroid medicine for treating mouth ulcers**




Corticosteroids are classified as hydrocortisone, prednisone, triamcinolone, dexamethasone, clobetasol, and mometasone. Glucocorticoids influence the metabolism of lipids, carbohydrates, proteins, calcium, and electrolytes.





## Oral Steroids: Types and Side Effects | Patient

### Inhaled vs. Oral Corticosteroids




**Inhaled**

- Treatment for persistent asthma
- Intended for long-term use
- Fewer and less severe effects such as headache, sore throat, common cold or flu, and muscle aches



**Oral**



- Treatment for severe asthma and/or attacks
- Intended for short-term usage
- More severe, diverse side effects such as nausea, acne, weight gain, and irregular heartbeat



verywell

Topical acyclovir can cause mild pain, burning, or stinging. 29. OTC Abreva (docosanol 10% cream) is applied at the first sign of a cold sore until the infection is healed. 27 It works by inhibiting the fusion of the virus with the human cell membrane, thereby blocking entry and subsequent viral replication.

## Oral thrush - Symptoms and causes - Mayo Clinic



# Protect Against Oral Thrush

- Brush your teeth twice a day and floss daily
- Do not share toothbrushes
- Limit caffeine consumption
  - Quit smoking
- See your dentist regularly
- Limit sugar consumption
  - Rinse with ½ tsp salt dissolved in 1 cup warm water
- Add cinnamon to your diet
- Drink a daily cup of unsweetened cranberry juice
- Eat fermented and starchy vegetables
- Swish with 2-3 drops of clove oil and 1 tbsp coconut oil for 20 minutes
- Supplement with garlic and vitamin C
- Drink pau d'arco tea or take a tablet
- Drink lemon juice
- Apply gentian violet 2-3 times daily

increased appetite. increased growth of face or body hair. headache. nausea, vomiting. skin problems, acne, thin and shiny skin. trouble sleeping. weight gain. This list may not describe all possible side effects. Call your doctor for medical advice about side effects.

## Systemic and Topical Steroids in the Management of Oral Mucosal Lesions



reddish purple lines on the arms, face, legs, trunk, or groin. redness of the face. small, red or purple spots on the skin. swelling of the stomach area. thin, fragile skin. thinning of the scalp hair. Other side effects not listed may also occur in some patients. If you notice any other effects, check with your healthcare professional.

- <https://groups.google.com/g/ripped-reckoners/c/4-KX9huWa1k>
- <https://git.owlcode.tech/vladislavdmtrievkw/app24/issues/1>
- <https://publiclab.org/notes/print/44754>