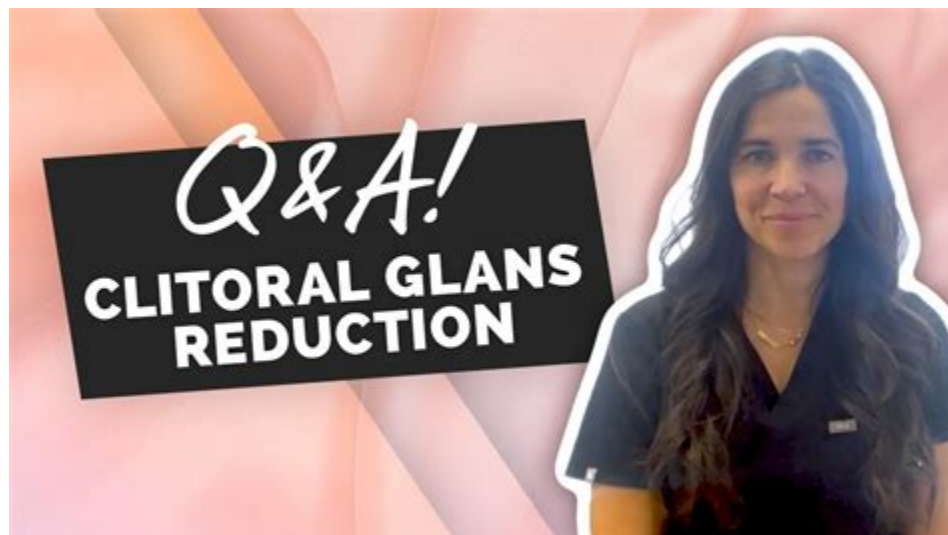

-Mary G. Treatment for Clitoromegaly Clitoropexy Clitoromegaly is a condition that causes an enlargement of the clitoris's erectile tissue. It is commonly caused by testosterone therapy such as Biote.



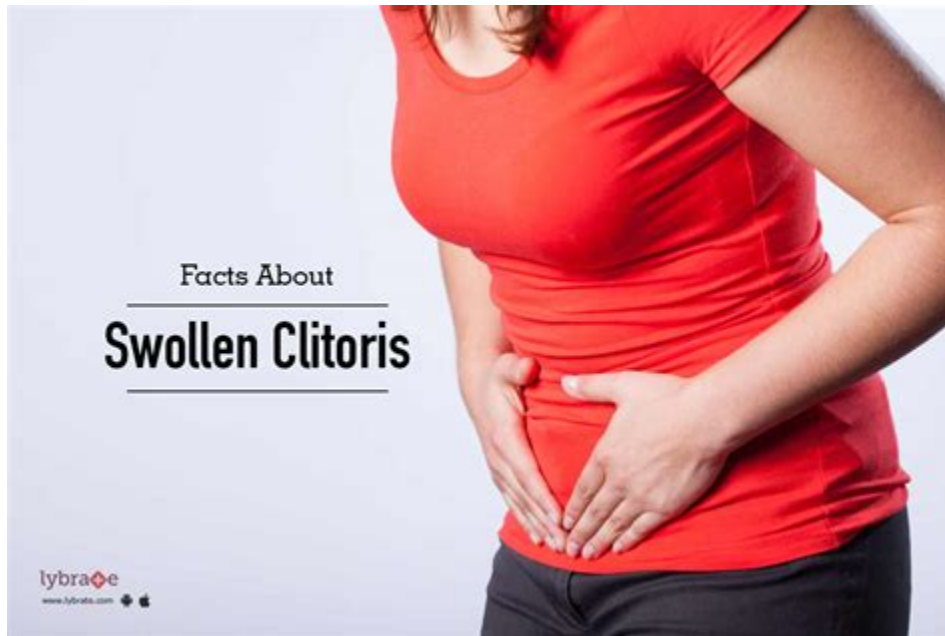??? SHOP NOW ONLINE ???

Treatment of the Enlarged Clitoris - PMC - National Center for .



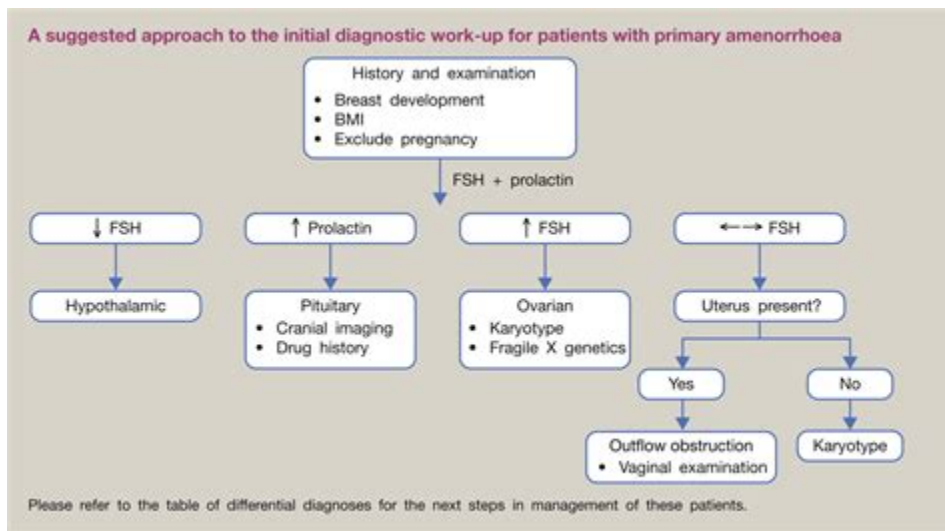
Overview What does an enlarged clitoris mean? An enlarged clitoris describes a clitoris that's larger than it should be. The medical term for an enlarged clitoris is clitoromegaly or macroclitoris. It happens when women and people assigned female at birth (AFAB) have swelling in the erectile tissues of their clitoris.

Enlarged clitoris | Evolutionary Steroids Research Forums



Clitoromegaly (or macroclitoris [1]) is an abnormal enlargement of the clitoris that is mostly congenital; it is otherwise acquired through deliberately induced clitoral enlargement e. g. body modification by use of anabolic steroids, including testosterone.

Primary amenorrhoea and clitoromegaly in a nulliparous woman .



Before and after steroids: some women admit they took them, while some claim it is all natural. Whatever their regimen, we can all agree it's extreme. 1 Heidi Krieger: the German shot put champion who was so masculinized by steroids that she later chose to become a man

CASE REPORT

A rare cause of clitoromegaly: Epidermoid cyst

Selman Karaci¹, Deniz Kulaksiz², Cagri Akin Sekerci³¹ Trabzon Kamuni Research and Training Hospital, Plastic & Reconstructive Surgery, Trabzon, Turkey;² Trabzon Kamuni Research and Training Hospital, Gynecology & Obstetrics, Trabzon, Turkey;³ Trabzon Kamuni Research and Training Hospital, Pediatric Urology, Trabzon, Turkey.

Summary Clitoromegaly due to non-hormonal causes is rare. In this case, we aimed to present an epidermoid cyst that caused clitoromegaly after traditional female circumcision. A 22-year-old African female was referred to our clinic with enlarged clitoris. There is a mobile, soft, non-fluctuant mass with a size of 6 cm originating from the clitoral region at physical examination. Under spinal anesthesia the clitoral mass was excised totally and labioplasty was performed. Histopathologic examination was reported as epidermoid cyst. Epidermoid cyst should be considered after hormonal reasons are excluded in patients with clitoromegaly who have a history of trauma.

KEY WORDS: Clitoromegaly; Epidermoid cyst; Female circumcision.

Submitted 1 February 2019; Accepted 1 April 2019

INTRODUCTION

Clitoromegaly often occurs with an increase in endogenous androgen release or by exogenous androgens in women. Non-hormonal causes of clitoral hypertrophy is rare and usually present with benign neoplasms. Fibroma, leiomyoma, angiokeratoma, pseudolymphoma, hemangioma, hemangiopericytoma, granular cell tumor and neurofibroma were reported as benign neoplasms causing clitoromegaly; carcinoma, endodermal sinus tumor, sarcoma, rhabdomyosarcoma, schwannoma, epithelioid hemangioendothelioma and lymphoma as malignant clitoral tumors (1). In this presentation, an asymptomatic clitoral mass due to epidermoid cyst developed following female circumcision was reported.

CASE REPORT

A 22-year-old African female was referred to our clinic with enlarged clitoris. The enlargement had been present since early adolescence period. She had a story of traditional female circumcision in early childhood. She had no systemic disease, hirsutism and obesity. She menses regularly every 28 days and secondary sex characteristics were normal. There was a mobile, soft, non-fluctuant mass with a size of 6 cm originating from the clitoral region in physical examination. Luteinizing hormone, follicle stimulating hormone, serum prolactin, serum cortisol and 17-hydroxyprogesterone were all found

No conflict of interest declared.

within the normal range. Bilateral ovaries and uterus were normal by pelvic ultrasonography. No structure for any male genital organ was observed. For this reason, disorders of sex development were excluded. It was reported as a massive cystic structure with no perfusion on pelvic magnetic resonance imaging. Under spinal anesthesia the clitoral mass was excised totally and labioplasty was performed. During surgery, glans and neurovascular bundle of the clitoris were not observed. It can be associated with previous female circumcision. There was no complication at the postoperative period. Histopathologic examination was reported as a 5 x 3 x 2.5 cm epidermoid cyst filled with keratinous material.

DISCUSSION

Clitoral hypertrophy may be congenital or acquired. Congenital forms are usually observed at birth and develop due to hormonal disorders. Acquired forms can be divided into two forms, hormonal or non-hormonal. Hormonal causes include hypertestosteronism, polycystic ovarian syndrome, virilizing tumors of the ovary or adrenal gland, and exogenous androgen exposure (2). Non hormonal causes are more and are associated with neoplasms.

Epidermoid cyst is one of the rare causes of non-hormonal acquired clitoromegaly. The epidermoid cyst may be intradermal or subcutaneously localized and surrounded by the epidermis wall. Epidermoid cyst is formed by keratinized squamous epithelium invagination into the dermis or subcutaneous tissue spontaneously or following trauma and filled with lamine keratin (3). Epidermal cysts often occupy the vulva or labia major. Clitoral epidermoid cyst can often be observed in African girls or women following trauma caused by genital mutilation (1). Spontaneous development without trauma is rare (2). Anderson-Mueller et al. presented a 17-year-old African-American girl with a painful clitoral mass. Patient had no female circumcision or any genital trauma. After the endocrinological causes were excluded, the neurovascular bundle of clitoris was preserved and the mass was excised. Pathology evaluation reported a benign squamous mucosa with submucosal edema, chronic inflammation, fibrosis, and mild vascular congestion (1). In our case, there was no trauma story and only traditional female circumcision for genital mutila-

Clitoral enlargement has been described in an 11-year-old together with asymmetry of both feet and a progressive asymmetric overgrowth of the lower limbs and toes [Criton et al. , 1995]. Beckwith-Wiedemann Syndrome. . The serum steroid profile showed elevated 16-hydroxysteroid and 3β-hydroxy-5ene steroid metabolites. The karyotype was 46,XX .

Do You Have an Enlarged Clitoris From . - Austin Urogynecology



Yet, in the past five years, the number of women requesting clitoral hood enlargement treatments has been increasing, he said. He injects women's clitoral hoods with hyaluronic acid fillers, which last about six months. Anastasatos charges between \$3,500 and \$4,500 for the procedure, which insurance does not cover.

These Women Spend Thousands Of Dollars To Medically Enlarge Their .



An excess of androgen hormones, like testosterone, can cause your clitoris to grow in size. High testosterone levels can occur naturally in your body or as a result of anabolic steroids. Women who .

Frontiers | Treatment of the Enlarged Clitoris



Anatomy The clitoris, like the penis, consists of two corpora cavernosa. While not having a defined corpora spongiosum, the clitoris does have the male equivalent of the glans, which consists of spongiosal tissue. Arterial supply branches from the internal pudendal artery that travels via Alcock's canal near the ischial tuberosity.

Clitoral Hood: Size, Appearance, and Effect on Orgasm - Healthline



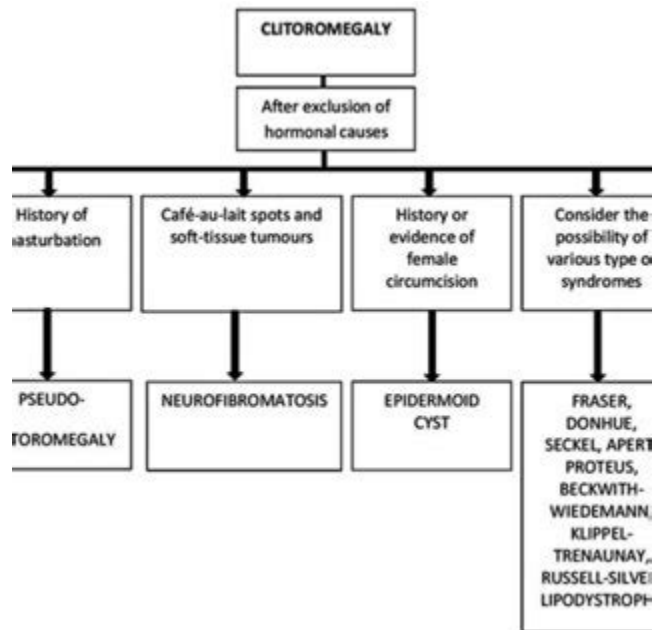
The discovery of an enlarged clitoris (clitoromegaly) . The steroid 11-deoxycortisol is the substrate for the enzyme and this is elevated in plasma with a high ratio of 11-deoxycortisol to cortisol (Khattab et al. , 2017) and raised tetrahydro-11-deoxycortisol in urine .

Anabolic-androgenic steroid use among women - ScienceDirect

	#	%
Duration of steroid use		
<Six months	18	20.22
Six months – one year	12	13.48
>One year	59	66.29
Aim of steroid use		
To treat medical problems	3	3.37
For muscle building	61	68.54
To participate in contests	20	22.47
Others reason	5	5.62
Forms of steroid use		
Tablet	13	14.61
injection	15	16.85
combination	61	68.54
How to use		
Short cycles	53	59.55
Long cycles	20	22.47
random	16	17.98
Source of steroid		
internet	15	16.85
Coach	49	55.06
pharmacy	8	8.99
friends	6	6.74
Others	11	12.36
Total	89	100

Methods The most common methods of clitoris enlargement are: Use of androgen containing creams on the clitoris [citation needed] Injection of testosterone for an extended time, as seen in transgender men and nonbinary people. Female bodybuilders who utilize testosterone may also experience clitoral growth.

Clitoromegaly in Childhood and Adolescence: Behind One Clinical Sign, a .



Management of the enlarged clitoris, because of its import for sexual function, has been and remains one of the most controversial topics in pediatric urology. Early controversy surrounding clitoroplasty resulted from many factors including an incomplete understanding of clitoral anatomy and incorrect assumptions of the role of the clitoris in sexual function.

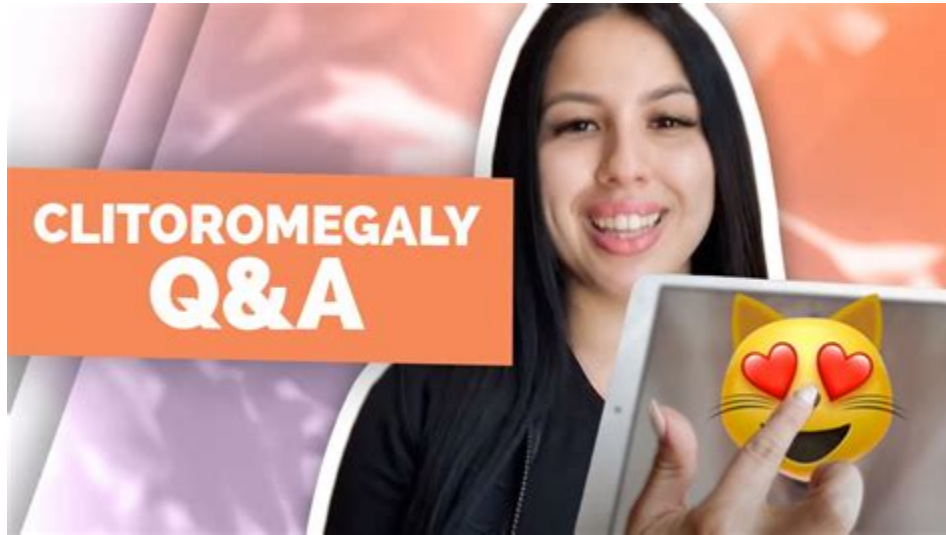Enlarged Clitoris: Causes, Treatment, Other Symptoms, and More - Healthline



When aroused, blood rushes to the erectile tissue that makes up the clit (the same tissue as in a penis),


causing it to become engorged. This is a clitoral erection. Is this the same process as.

Clitoromegaly - Pictures, Size, Symptoms, Causes, Treatment



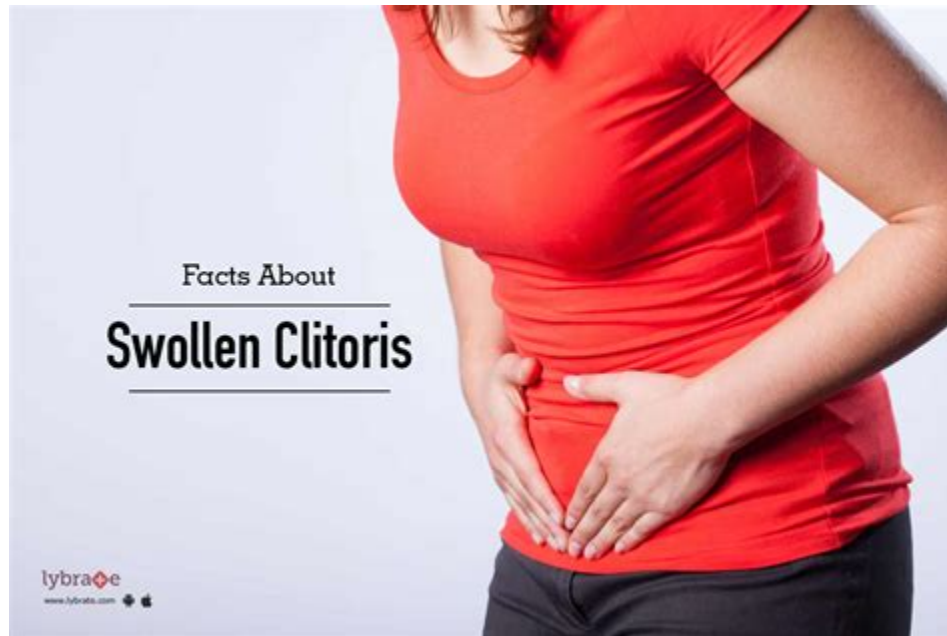Clitoris pain usually happens when your clitoris or vulva (your external genitals) get damaged or injured. Your clitoris is a pleasure organ found in the front of your vagina and on top of your urethra (the hole you pee from). It contains thousands of sensory nerves, some of which extend more than 5 inches inside your body.

8 Women Before and After Steroids - Oddee



This condition is harmless because it doesn't cause any damage to health. However, it gets the attention of medical experts because it happens due to underlying hormonal changes. It is recommended to visit a specialist if you feel enlargement of clitoris.

The 5 Major Causes of Enlarged Clitoris - Public Health



Address hormonal imbalances: Hormonal imbalances can cause an enlarged clitoris. Treatment may involve medication to regulate hormone levels or surgery to remove excess tissue. Change medications: Certain medications such as steroids, hormones, and some antidepressants can cause clitoral enlargement.

Effects of testosterone treatment on clitoral haemodynamics in women .

Journal of Endocrinological Investigation
https://doi.org/10.1007/s40618-021-01598-1

ORIGINAL ARTICLE



Effects of testosterone treatment on clitoral haemodynamics in women with sexual dysfunction

S. Cipriani¹ · E. Maseroli¹ · V. Di Stasi¹ · I. Scavello¹ · T. Todisco¹ · G. Rastrelli¹ · M. Fambrini² · F. Sorbi² · F. Petraglia² · E. A. Jannini³ · M. Maggi^{4,5} · L. Vignozzi^{1,5}

Received: 3 January 2021 / Accepted: 20 May 2021
© The Author(s) 2021

Abstract

Purpose To explore the effects of 6-month systemic testosterone (T) administration on clitoral color Doppler ultrasound (CDU) parameters in women with female sexual dysfunction (FSD).

Methods 81 women with FSD were retrospectively recruited. Data on CDU parameters at baseline and after 6 months with four different treatments were available and thus further longitudinally analyzed: local non-hormonal moisturizers (NH group), $n = 37$; transdermal 2% T gel 300 mcg/day (T group), $n = 23$; local estrogens (E group), $n = 12$; combined therapy (T + E group), $n = 9$. Patients underwent physical, laboratory, and genital CDU examinations at both visits and completed different validated questionnaires, including the Female Sexual Function Index (FSFI).

Results At 6-month visit, T therapy significantly increased clitoral artery peak systolic velocity (PSV) when compared to both NH ($p < 0.0001$) and E ($p < 0.0001$) groups. A similar increase was found in the T + E group ($p = 0.039$ vs. E). In addition, T treatment was associated with significantly higher FSFI desire, pain, arousal, lubrication, orgasm, and total scores at 6-month visit vs. baseline. Similar findings were observed in the T + E group. No significant differences in the variations of total and high-density lipoprotein-cholesterol, triglycerides, fasting glycemia, insulin and glycated hemoglobin levels were found among the four groups. No adverse events were observed.

Conclusion In women complaining for FSD, systemic T administration, either alone or combined with local estrogens, was associated with a positive effect on clitoral blood flow and a clinical improvement in sexual function, showing a good safety profile.

Trial registration number NCT04336891; date of registration: April 7, 2020.

Keywords Female sexual dysfunction · Clitoris · Ultrasound · Testosterone treatment in women · Treatment for female sexual dysfunction · Genital blood flow

S. Cipriani and E. Maseroli equally contributed

✉ L. Vignozzi
linda.vignozzi@unifi.it

¹ Andrology, Women's Endocrinology and Gender Incongruence Unit, Department of Experimental, Clinical and Biomedical Sciences "Mario Serio", University of Florence, Viale Gaetano Pieraccini 6, 50139 Florence, Italy

² Department of Experimental, Clinical and Biomedical Sciences "Mario Serio", Gynecology Unit, University of Florence, Florence, Italy

³ Endocrinology and Medical Sexology (ENDOSEX), Department of Systems Medicine, University of Rome Tor Vergata, Rome, Italy

⁴ Endocrinology Unit, Department of Experimental, Clinical and Biomedical Sciences "Mario Serio", University of Florence, Florence, Italy

⁵ I.N.B.B. (Istituto Nazionale Biostrutture e Biosistemi), Rome, Italy

Published online: 12 June 2021

Springer

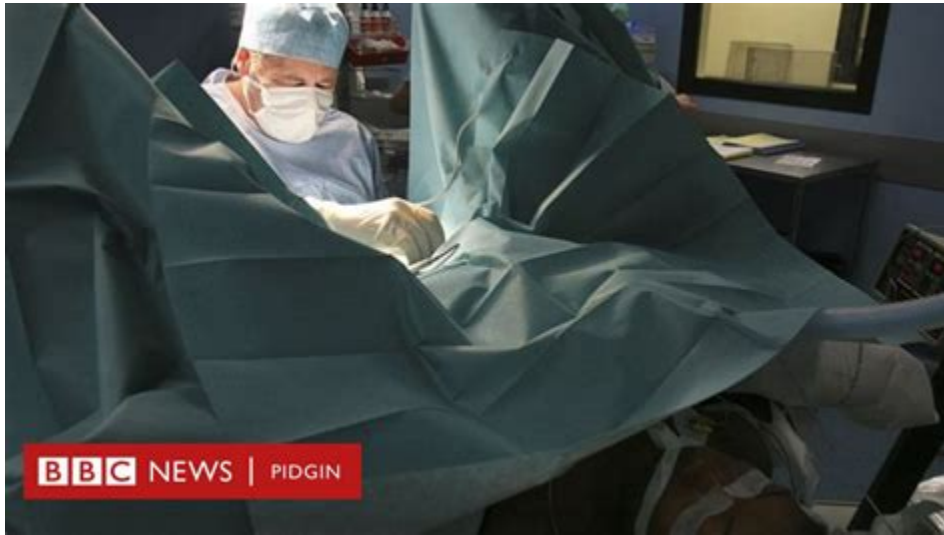Steroids that Can Make a Woman Clitoris Bigger Clitoromegaly is a term used to describe an enlarged clitoris. Clitoromegaly can be congenital or caused by certain medical conditions, in this article, we will discuss the side effects that anabolic steroids can have on making the clitoris bigger.

Enlarged clitoris: Symptoms and causes - Medical News Today



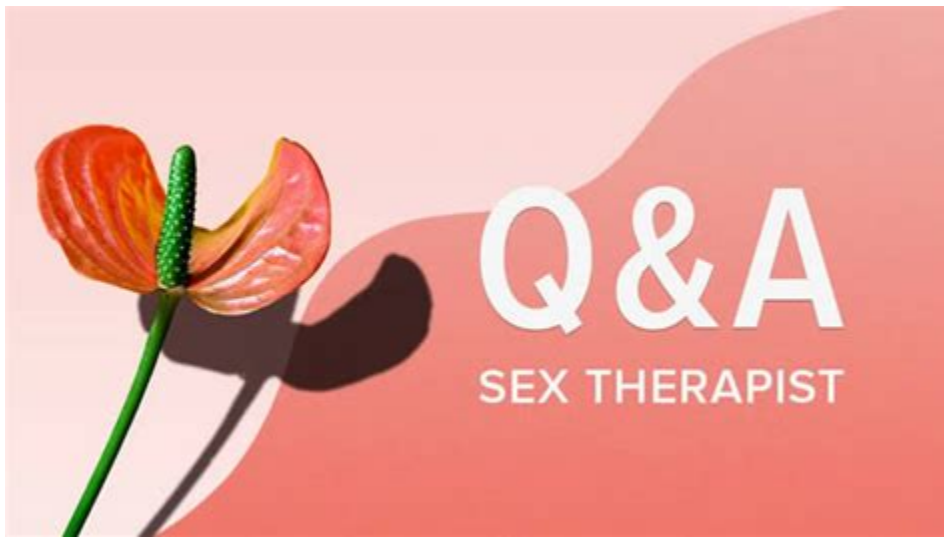Clitoris was enlarged to 3 cm in length and 1.8 cm in width. Glans was well formed. Labia minora formed hood of the prepuce. Per-speculum, per-vaginal and per-rectal examinations were unremarkable. There was no significant history in the family of abnormal genitalia or congenital disorders or diabetes mellitus. . Use of exogenous steroids .

Clitoromegaly - Wikipedia



Results. At 6-month visit, T therapy significantly increased clitoral artery peak systolic velocity (PSV) when compared to both NH ($p < 0.0001$) and E ($p < 0.0001$) groups. A similar increase was found in the T + E group ($p = 0.039$ vs. E). In addition, T treatment was associated with significantly higher FSFI desire, pain, arousal, lubrication, orgasm, and total scores at 6-month visit vs. baseline.

Clitoral Erections: Why It Happens, How It Feels, Tips, More - Healthline



A common side effect of testosterone replacement therapy for women is an enlarged clitoris, also referred to as clitoromegaly. While a small amount of enlargement of the clitoral tissue may not bother some women, some may find that the change in appearance is drastic enough to be bothersome.

Vaginal Burning

<u>Symptoms</u>	<u>Avoid</u>
	
<ul style="list-style-type: none">• Rashes in or around the vagina• Painful sexual intercourse• Persistent vaginal discharge	<ul style="list-style-type: none">• Bubble bath products• Harsh Soaps• Menstrual pads• Scented toilet papers

 DxSaver.com

- Vaginal burning is relatively a common complaint. It can occur due to a variety of diseases, disorders or conditions
- Vaginal burning is one of the symptoms of Sexually transmitted diseases (STD)

Yes, it does. When you become sexually aroused, your glans clitoris engorges, just like a penis. This swelling is usually enough to move your hood aside, exposing your glans. If your hood is .

Enlarged Clitoris (Clitoromegaly): Causes & Treatment - Cleveland Clinic



Jan 22, 2015. #18. My wife has done a couple cycles, mainly with var up to 25mg/day and separate cycle ~40mg test E/wk. She did get enlarged clit, and it did go away at end of cycle. She was extremely sensitive during this time, which made us have to change up our foreplay a bit but it didn't bother her.

Clitoral enlargement methods - Wikipedia



In addition, women are at risk of developing undesired masculine traits, such as increased facial and body hair, deeper voice, reduced breast volume, enlarged clitoris and gonadal dysfunction resulting in irregular or absent menstruation and reduced fertility (Eklöf, Thurelius, Garle, Rane & Sjöqvist, 2003; Franke & Berendonk, 1997; Gruber & Po.

Steroids That Cause Clitoromegaly in Women



Causes in adults Sexual excitement Sexual arousal causes the clitoris to swell. An adult's clitoris usually swells because of sexual excitement or arousal. During arousal, more blood flows to.

- <https://publiclab.org/notes/print/43625>
- <https://publiclab.org/notes/print/44406>
- <https://publiclab.org/notes/print/41505>